50 Calcifying and Ossifying Disorders of the Skin

Daniela Kroshinsky and Janet A. Fairley

Chapter Contents

Cutaneous Calcification 796
Cutaneous Ossification (Osteoma Cutis) 802
Laboratory Evaluation of Patients with Cutaneous Calcification and Ossification 804

Synonyms: ■ Calcinosis cutis: cutaneous calcification ■ Osteoma cutis: cutaneous ossification ■ Calciphylaxis: calcific uremic arteriolopathy; calcifying panniculitis; uremic gangrene syndrome ■ Subepidermal calcified nodule: solitary congenital nodular calcification; Winer's nodular calcinosis

Key features

- Calcium regulates several key physiologic events in the skin, including epidermal proliferation, differentiation, and cell–cell adhesion
- Disruption of normal calcium regulatory pathways can lead to calcification and/or ossification of the skin
- Five major types of cutaneous calcification are seen: *dystrophic*, in which pre-existing damage to the skin results in calcium deposits; *metastatic*, where systemic metabolic disorders lead to calcium deposits in the skin and often other tissues; *iatrogenic*, as a result of medical therapy or testing; *idiopathic*, in which no cause can be identified; and *mixed*, a combination of metastatic and dystrophic
- In cutaneous ossification, there is deposition of calcium and phosphorus as hydroxyapatite crystals within a protein matrix; it can occur in conjunction with calcification or primarily in a number of genetic syndromes
- Correct classification of calcifying disorders requires an evaluation of calcium-phosphate metabolism and examination for associated systemic abnormalities
- Treatment of calcifying disorders is difficult with removal of triggers and correction of any associated disorder, such as hyperparathyroidism, essential for preventing progression. Surgical excision may be useful in circumscribed disease that interferes with function while efficacy of agents that modify calcium metabolism is based primarily upon case series

INTRODUCTION

Calcium plays a vital role in regulating key physiologic events in many tissues, including the skin. In the epidermis, calcium assists in regulating major functions, including proliferation, differentiation, and cell–cell adhesion. Control of intra- and extracellular calcium concentrations and maintenance of gradients are essential for its regulatory role. When factors that regulate calcium in the skin are disrupted, either by local or systemic events, cutaneous calcification or ossification as well as acantholysis and dyskeratosis can develop.

Calcification arises from the deposition of amorphous, insoluble calcium salts, while ossification results from deposition of calcium and phosphorus in a proteinaceous matrix as hydroxyapatite crystals. Ossification may follow pre-existing calcification in the skin, but in most disorders one form of calcium deposition predominates. While each of the calcifying and ossifying disorders of the skin is rare, as an aggregate finding calcium deposition within the skin is not uncommon.

CUTANEOUS CALCIFICATION

Calcifying disorders of the skin are generally divided into five broad categories: dystrophic, metastatic, idiopathic, iatrogenic, and mixed calcification (Table 50.1)[1,2]. *Dystrophic* calcification occurs in the setting of localized tissue damage, without an underlying metabolic abnormality in calcium regulation. Theoretically, dystrophic calcification occurs because the underlying disease process damages cell membranes, allowing calcium influx and subsequent intracellular crystallization. Alternatively, the acidity that accompanies cell damage may disrupt normal processes that inhibit calcification. In contrast, *metastatic* calcification occurs in normal tissue when there is dysfunction of calcium regulatory systems. When no known local or systemic factors can be identified, the calcification is categorized as *idiopathic*, and that related to medical therapy or testing is *iatrogenic*. *Mixed* calcification arises when metastatic calcification due to an underlying metabolic abnormality acts as a trigger for dystrophic calcification.

Dystrophic Calcification

Autoimmune connective tissue disease

Dystrophic calcification may be seen in any of the autoimmune connective tissue diseases (AI-CTDs), but it is most common in childhood dermatomyositis and in the localized form of systemic sclerosis, also known as CREST (*c*alcification, *R*aynaud phenomenon, *e*sophageal dysmotility, *s*clerodactyly, and *t*elangiectasia) syndrome. As a comparison, cutaneous calcification develops in 10%–20% of patients with adult dermatomyositis, whereas it occurs in up to 50% of children with the disease[3–5]. The presence of dermatomyositis-associated calcinosis correlates with longer disease duration, fingertip ulceration, and anti-NXP-2 autoantibodies, while a negative correlation exists with anti-transcriptional intermediary factor 1-γ antibodies[3]. Small deposits may occur in the skin or larger firm masses may begin in the muscle groups most severely affected by the disease. The most frequently involved sites are the elbows, knees, buttocks, and shoulders (see Fig. 42.9). Extrusion of calcium through the skin causes significant morbidity with pain and secondary infection.

In calcinosis universalis, the most severe form of dystrophic calcification, there is diffuse involvement with sheet-like masses of calcium. Calcification occurs along fascial planes, often leading to severe functional impairment. Aggressive treatment of dermatomyositis with immunosuppressive agents and/or IVIg may be warranted to try to limit this serious complication (see Ch. 42). However, once calcification has developed, the effectiveness of these therapies is quite variable.

The localized (CREST) variant of systemic sclerosis is the other AI-CTD in which cutaneous calcification is frequently seen. Calcification is usually less severe than in dermatomyositis and is usually restricted to the hands and upper extremities (Fig. 50.1); it is also seen over bony prominences and tendons. Extrusion of white chalky material is sometimes followed by localized ulceration, often at sites of trauma such as the digits. Calcinosis universalis can occur in systemic sclerosis, but much less frequently than in dermatomyositis.

Dystrophic calcification has occasionally been reported in chronic cutaneous, acute systemic, and subacute cutaneous lupus erythematosus as well as generalized morphea (Fig. 50.2)[6,7]. Calcification may also occur within lesions of lupus panniculitis. In systemic lupus erythematosus, calcification is most often an asymptomatic radiologic finding.

Downloaded for Anonymous User (n/a) at Egyptian Knowledge Bank from ClinicalKey.com by Elsevier on March 10, 2024. For personal use only. No other uses without permission. Copyright ©2024. Elsevier Inc. All rights reserved.

DISORDERS OF CUTANEOUS CALCIFICATION
Dystrophic
• Autoimmune connective tissue diseases, especially dermatomyositis, CREST • Panniculitis • Cutaneous tumors or cysts, e.g. pilomatricomas, pilar cysts • Infections, especially parasitic • Trauma, including "heel sticks" in neonates, injection sites, surgical scars • Chronic graft-versus-host disease • Genetic disorders, e.g. pseudoxanthoma elasticum, Ehlers–Danlos syndrome
Metastatic

• Advanced chronic kidney disease
  • Calciphylaxis*
  • Benign nodular calcification of renal disease
  • Tumoral calcinosis
• Hypervitaminosis D
• Milk–alkali syndrome
• Sarcoidosis
• Tumoral calcinosis (familial)
• Hyperparathyroidism
• Neoplasms (e.g. multiple myeloma, adult T cell leukemia/lymphoma, SCC of the lung or head and neck)

Idiopathic
• Idiopathic calcified nodules of the scrotum • Subepidermal calcified nodule • Tumoral calcinosis (sporadic) • Milia-like calcinosis
Iatrogenic
• Extravasation of intravenous solutions containing calcium or phosphate • Application of calcium-containing electrode paste for EMGs and EEGs • Application of calcium alginate dressings to denuded skin • Fibroblast growth factor receptor inhibitors† • Organ transplantation, especially liver • Gadolinium (nephrogenic systemic fibrosis)
*Can occasionally occur in the setting of severe primary hyperparathyroidism and, less often, in the absence of a clearly identifiable trigger. †Calcinosis cutis and calciphylaxis due to hyperphosphatemia.

Table 50.1 Disorders of cutaneous calcification. CREST, *c*alcification, *R*aynaud phenomenon, *e*sophageal dysmotility, *s*clerodactyly and *t*elangiectasia; EEG, electroencephalogram; EMG, electromyography; SCC, squamous cell carcinoma.

Fig. 50.1 Dystrophic calcification in a patient with the localized form of systemic sclerosis (CREST syndrome).

Fig. 50.2 Radiograph of calcinosis cutis in a patient with generalized morphea. Areas that were previously firm became rock-hard and lesions of perforating calcinosis cutis (transepidermal elimination) developed on both legs. *Courtesy Jean L. Bolognia, MD.*

Treatment of dystrophic calcification

The management of dystrophic calcification can be challenging. Therapies include a low calcium and phosphate diet, aluminum hydroxide, and bisphosphonates, as well as management of the underlying disorder, although no controlled trials have convincingly shown consistent clinical improvement. While long-term treatment with diltiazem has been reported to decrease the size of calcium deposits, presumably through its effect on calcium transport into cells, its efficacy is variable and months to years of treatment may be required for extensive calcification[8,9]. In case reports and series, minocycline, colchicine, probenecid, IVIg, and JAK inhibitors have demonstrated some efficacy. Application of topical sodium thiosulfate 250 mg/ml [12.5 gm/50 ml] compounded 1 : 1 with petrolatum applied daily) can lead to resolution, while larger lesions may variably respond to intralesional injections (Table 50.2)[10–13].

Surgical excision is appropriate in selected patients with localized masses that are painful or interfere with function, but recurrences can occur. Laser therapy and extracorporeal shock wave lithotripsy represent additional localized therapeutic options[13].

Panniculitis

Any lobular panniculitis may develop focal dystrophic calcification, including pancreatic panniculitis, lupus profundus, and subcutaneous fat necrosis of the newborn (see Ch. 100). In the latter, calcium deposits are small and are most easily noted radiologically; occasionally, more widespread deposits may be seen[14].

Genetic disorders

A number of genetic disorders may be accompanied by cutaneous calcification, including *pseudoxanthoma elasticum* (PXE; see Ch. 97). The coexistence of typical elastic fiber calcification along with small discrete foci of cutaneous calcification or ossification has been reported[15,16]. PXE most frequently results from inactivating mutations in *ABCC6* which encodes a membrane transporter system[17]. ABCC6 directly mediates the sinusoidal release of ATP from the liver, which is then converted to AMP and inorganic pyrophosphate (PPi) within the liver vasculature[18,19]. PPi normally prevents the matrix calcification that is thought to create the findings in PXE[19]. In addition, serum levels of fetuin-A, another major anti-mineralization protein, are significantly reduced in PXE patients[18,20]. These factors, combined with impaired carboxylation of the inhibitor matrix Gla protein, may allow for increased responsiveness to pro-calcifying stimuli and unchecked calcification of elastic fibers in affected tissues[20,21].

Downloaded for Anonymous User (n/a) at Egyptian Knowledge Bank from ClinicalKey.com by Elsevier on March 10, 2024. For personal use only. No other uses without permission. Copyright ©2024. Elsevier Inc. All rights reserved.

SODIUM THIOSULFATE – INTRALESIONAL AND INTRAVENOUS ADMINISTRATION	
Intralesional	
• 250 mg/ml solution • Interventions to address significant associated pain include: (1) premedication (e.g. acetaminophen, oxycodone, hydromorphone); (2) 1 : 1 dilution with 2% lidocaine without epinephrine (adrenaline); and (3) use of small gauge needles and low volume syringes • Inject solution into the skin surrounding the ulceration (not the ulcer) every 1 cm* not to exceed 25 g • Injected weekly until resolution of active erythema and purpura then as needed for new lesions	
Intravenous	
• If receiving hemodialysis, 12.5 g three times per week during the last hour of hemodialysis (first 3 doses) then can increase to 25 g three times per week as tolerated • If receiving peritoneal dialysis, 25 g weekly • If not receiving hemodialysis, can be dosed up to 25 g daily • Continue until resolution of active erythema and purpura	
Side effects†	
• Nausea, vomiting • Volume overload due to sodium load (intravenous)‡ • Hypotension • QT prolongation	• Anion gap metabolic acidosis (thiosulfuric acid) • Reduced bone density • Headache

*Injected in a manner similar to the injection of lidocaine for local anesthesia.
†May be reduced by decreasing the dosage, increasing the interval (nonuremic patients), and/or changing the intravenous solution from saline-based to 5% dextrose in water.
‡Cardiology consultation for those with cardiovascular disease.

Table 50.2 Sodium thiosulfate – intralesional and intravenous administration. The risk:benefit ratio must be considered before injecting lesions overlying bone. For injections into large dense calcium deposits, larger bore needles (e.g. 14g) are sometimes employed. g, gram. From references 37, 45, 55, 59, 62–65.

Ehlers–Danlos syndrome encompasses multiple disorders in which genetic mutations lead to abnormal collagen synthesis, metabolism, or function (see Ch. 95). Patients develop hard subcutaneous nodules known as spheroids or spherules over bony prominences, which are thought to represent herniated fat lobules that have calcified (see Ch. 97). It is also possible that minor trauma results in scar tissue which then becomes a focus for dystrophic calcification[22]. Of note, similar calcifications can occur within the breast in these patients and their detection by mammography may lead to false-positive radiographic findings for breast carcinoma.

Dystrophic calcification may also be seen in patients with *porphyria cutanea tarda* (PCT; see Ch. 49). It occurs most often in patients with longstanding disease who develop sclerodermoid changes and secondary calcification within these areas[23]. As with the other lesions of PCT, calcification appears most often in the head and neck region or on the dorsal surface of the hands. Ulceration has also been reported, although rarely, in association with these lesions.

Other rare genetic syndromes in which cutaneous calcification may be seen include *Werner syndrome* and *Rothmund–Thomson syndrome* (see Ch. 63). *Cerebral amyloid angiopathy*, an autosomal dominant condition due to mutations in the gene encoding the amyloid precursor protein, can present with dementia, patchy leukoencephalopathy, hemorrhagic stroke, external carotid artery dysplasia, and occipital calcifications[24]. Microcalcification of the dermal blood vessels may also be seen, and while the latter is asymptomatic, dermatologists might be called upon to biopsy the skin as a diagnostic measure.

Infections

Infections, particularly parasitic, can lead to dystrophic calcification. Calcified cysts form around larvae or worms, including *Onchocerca volvulus* and the tapeworm *Taenia solium*. Intrauterine herpes simplex viral infections may cause annular plaques of calcinosis cutis in newborns.

Neoplasms

Incidental calcification has been noted in a large number of benign and malignant tumors of the skin. Up to 75% of pilomatricomas develop calcification and in 15%–20% there is evidence of ossification. A chalky, calcium-containing material may drain from the surface of these tumors. Activating mutations in the β-catenin gene have been demonstrated in sporadic pilomatricomas[25]. Other calcifying adnexal tumors or cysts include basal cell carcinomas, pilar cysts, epidermoid cysts, and chondroid syringomas[26]. Rarely, melanocytic nevi, atypical fibroxanthomas, pyogenic granulomas, trichoepitheliomas, and seborrheic keratoses have been reported to calcify.

Fig. 50.3 Dystrophic calcification in an infant at the site of a previous "heel stick" for obtaining blood. *Courtesy Julie V. Schaffer, MD.*

Other

Trauma, "heel sticks" (for obtaining blood in neonates; Fig. 50.3), subcutaneous or intramuscular injection sites, surgical and burn scars, and keloids have also been reported as triggers of dystrophic calcification. Localized or widespread cutaneous calcification may also be seen in chronic graft-versus-host disease[27].

Metastatic Calcification

Renal disease

The most common cause of metastatic calcification is advanced chronic kidney disease (Fig. 50.4). In patients with renal failure, there is an impaired ability to clear phosphate and impaired activation of vitamin D_3, as 1-α hydroxylation occurs in the kidney. Impaired production of 1,25-dihydroxyvitamin D_3 leads to decreased absorption of calcium from the intestine and hypocalcemia. Hypocalcemia, in turn, induces increased secretion of parathyroid hormone (PTH) and subsequent mobilization of calcium and phosphate. The serum calcium concentration is normalized, but significant hyperphosphatemia may develop, leading to elevation of the calcium × phosphate solubility product and resultant metastatic calcification.

Benign nodular calcification usually develops in the setting of prolonged secondary hyperparathyroidism due to advanced chronic kidney disease. Clinically, there are large deposits of calcium in the skin and subcutaneous tissue, often in periarticular sites. The number and size correlate with the severity of the hyperphosphatemia. Lesions are usually asymptomatic except for pain from pressure placed on surrounding structures. Normalization of serum calcium and phosphate levels may result in resorption of the lesions; however, if larger deposits interfere with function, surgical removal is recommended.

In renal transplant recipients, deposition of calcium within the skin has been reported following subcutaneous administration of low-molecular-weight heparin (nadroparin). Nodules with secondary ulceration developed at the sites of the heparin injections, but the process was self-limited and resolved following discontinuation of the nadroparin. The calcium content of the heparin in combination with hyperphosphatemia due to renal dysfunction was hypothesized as the underlying pathogenic mechanism[28].

Downloaded for Anonymous User (n/a) at Egyptian Knowledge Bank from ClinicalKey.com by Elsevier on March 10, 2024. For personal use only. No other uses without permission. Copyright ©2024. Elsevier Inc. All rights reserved.

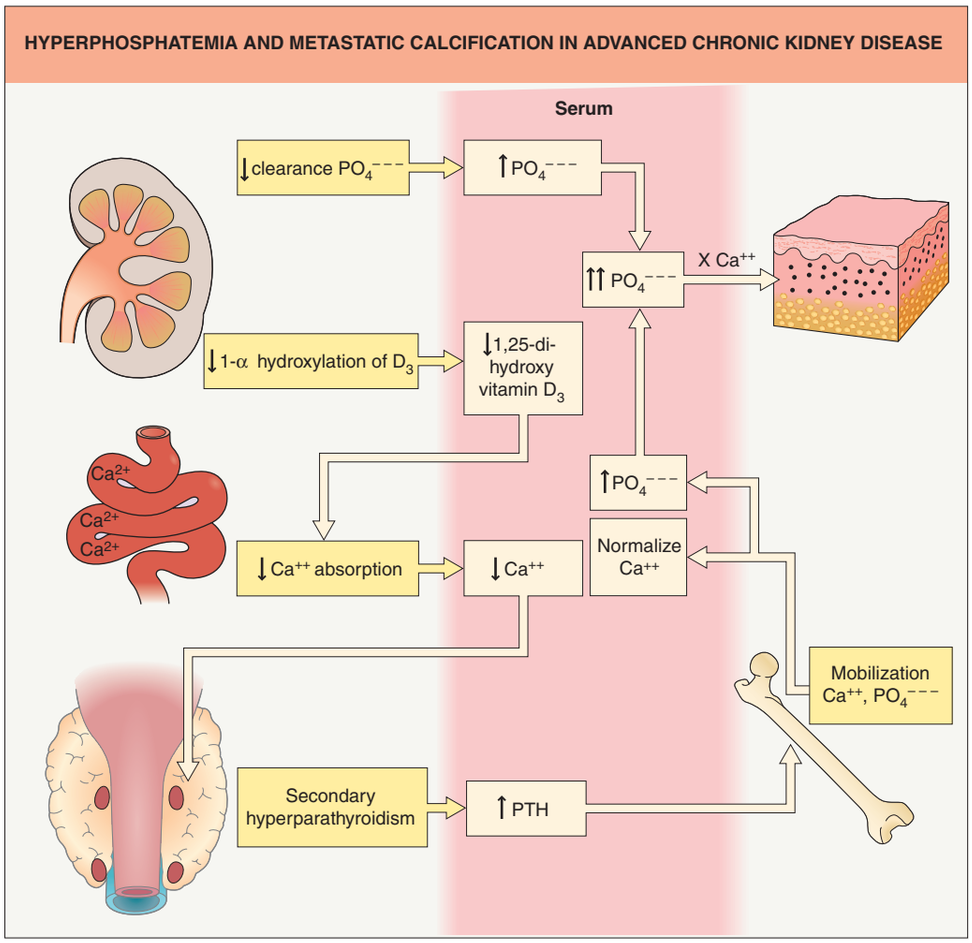

Fig. 50.4 Mechanisms of hyperphosphatemia and metastatic calcification in patients with advanced chronic kidney disease. PTH, parathyroid hormone.

Milk–alkali syndrome

Ingestion of excessive amounts of calcium-containing foods or antacids can lead to hypercalcemia and the milk–alkali syndrome. Patients with milk–alkali syndrome have acute manifestations including nephrocalcinosis, irreversible renal failure, and diffuse subcutaneous calcification.

Hypervitaminosis D

Chronic ingestion of supraphysiologic doses of vitamin D can lead to hypercalcemia and hypercalciuria. Clinical signs include weakness and lethargy, nausea, headache, and polyuria. Nephrolithiasis and calcinosis cutis may occur. Hypercalcemia is also seen in patients with sarcoidosis secondary to increased calcium absorption due to 1,25-dihydroxyvitamin D production by the granulomas. For other causes of metastatic cutaneous calcification, see Table 50.1.

Mixed Calcification

In mixed calcification, there is a combination of metastatic and dystrophic calcification, which is initiated by calcium dysregulation and then propagated by trauma.

Calciphylaxis

Calciphylaxis is a thrombotic vasculopathy that is characterized by microvascular deposition of calcium and subsequent thrombosis that results in ischemic necrosis of the skin and soft tissues[29,30]. While the majority of patients have severe or end-stage chronic kidney disease (CKD) requiring dialysis, nonuremic calciphylaxis can occur and has a better prognosis.

Early lesions usually present as poorly demarcated, often symmetric, extremely painful patches of erythema or livedo reticularis that progress to retiform purpura. Lesions favor areas with abundant adipose tissue such as the breasts and girdle area or sites of trauma, but they can also involve the distal extremities and penis (Fig. 50.5A,B)[29]. Bullae or a dusky gray color may then develop, signifying imminent tissue necrosis and the appearance of ulcerations with black, leathery eschars (Fig. 50.5C). Often, there is surrounding subcutaneous induration that extends beyond the margins of the visibly active lesions and may have a peau d'orange appearance; this can be helpful in distinguishing calciphylaxis from other forms of retiform purpura.

Early recognition and treatment is imperative because secondary infection and sepsis can develop as well as internal organ involvement. One-year mortality rates range from 30%–80%, with proximal lesion location and ulceration associated with a higher risk of death[29–32]. Nonuremic calciphylaxis is associated with lower one-year mortality rates which range from ~25% (all causes) to ~10% (when limited to calciphylaxis-related complications)[32].

The causes of calciphylaxis have not been fully elucidated. Selye, who coined the term calciphylaxis in 1961, suggested a "sensitizer plus challenger" model in which an underlying metabolic dysfunction involving serum levels of calcium and phosphate (e.g. secondary hyperparathyroidism) predisposed an individual to calciphylaxis. However, a second incident, or challenger, such as trauma or increased calcium load, ultimately resulted in calcium deposition and lesion formation[29,33,34]. In fact, new lesion formation has been reported following subcutaneous insulin or heparin injections and at sites of biopsies or aggressive debridement.

Additional contributing factors include thrombophilia (e.g. protein C or S deficiency, antiphospholipid antibodies) and alterations of vitamin K-dependent anti-calcification proteins such as fetuin-A and matrix Gla protein (see above)[35–38]. For vascular calcification to occur, an important step is the transdifferentiation of vascular smooth muscle cells into osteoblast-like cells. Phosphates, inflammatory mediators within the vessel wall, and bone morphogenic protein (BMP)-2 have all been proposed as potential stimuli for this conversion. In addition to matrix Gla protein and fetuin-A, BMP-7, osteoprotegerin, and phosphatonins are possible positive or negative regulators of this process[39]. Of note, patients who develop calciphylaxis have lower levels of anti-calcification proteins. Vitamin K is necessary to produce the active carboxylated forms of these proteins and a reduced level or inhibition of vitamin K is a known risk factor for calciphylaxis (see Ch. 23).

Downloaded for Anonymous User (n/a) at Egyptian Knowledge Bank from ClinicalKey.com by Elsevier on March 10, 2024. For personal use only. No other uses without permission. Copyright ©2024. Elsevier Inc. All rights reserved.

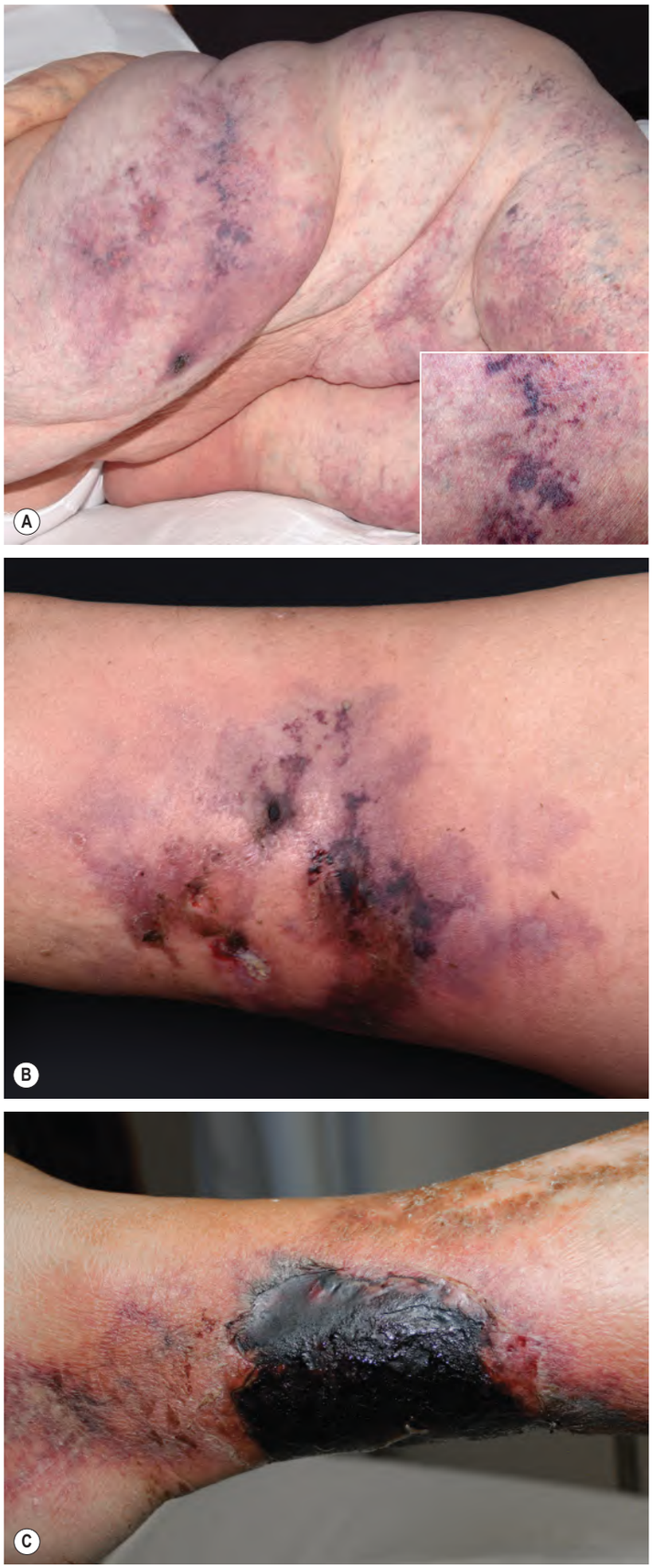

Fig. 50.5 Calciphylaxis in three patients with advanced chronic kidney disease. A Large reticulated violaceous plaques in an obese woman. Centrally, there is retiform purpura (inset) which precedes the ulcerations that are also present. **B** Irregular violaceous plaques on the leg with retiform purpura and hemorrhagic crusts overlying ulcerations. **C** Large ulceration with leathery black eschar. Retiform purpura and scarring are seen in the surrounding skin. *A, B, Courtesy Lorenzo Cerroni, MD.*

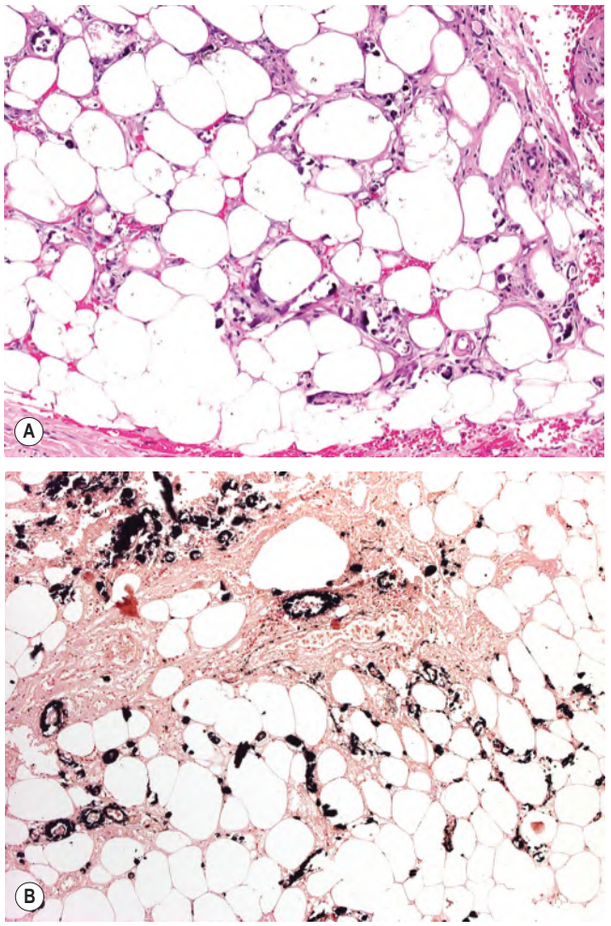

Fig. 50.6 Calciphylaxis – histopathologic features. A Perivascular deposition of calcium is seen within the walls of blood vessels in the subcutaneous fat. **B** Staining for calcium (von Kossa) highlights calcium deposition within blood vessel walls (black circular deposits) as well as focal, irregular calcification of connective tissue. Of note, even when the clinical lesions are impressive, the degree of calcification seen histologically may be subtle and clinical suspicion should remain high despite the absence of overt calcium deposits. *Courtesy Lorenzo Cerroni, MD.*

Additional risk factors include severe or end-stage CKD, dialysis, obesity, diabetes mellitus, AI-CTDs, and female sex as well as warfarin exposure, corticosteroids, and liver disease[29]. Hyperparathyroidism, calcium supplementation, and vitamin D intake are also risk factors, with the latter possibly related to stimulation from the conversion of vascular smooth muscle cells into osteoblast-like cells[40]. In nonuremic calciphylaxis, rapid weight loss, as seen in gastric bypass surgery, has emerged as a risk factor[41,42].

Diagnosis of calciphylaxis

Originally, calciphylaxis was thought to arise primarily in the setting of an elevated calcium × phosphate product. However, more recent studies have shown no statistical differences in the serum levels of calcium, phosphate, and PTH or the calcium × phosphate product in those with calciphylaxis compared to control dialysis patients at the time of presentation. The possible exception is elevations in time-averaged calcium × phosphate products or phosphate levels in affected individuals[43]. Nonetheless, initial evaluation should include a comprehensive metabolic panel, calcium, phosphorus, and PTH levels, and a complete coagulation profile.

While skin biopsy is currently considered the gold standard for diagnosing calciphylaxis, its role is controversial given the associated low sensitivity and specificity and risk of complications (e.g. ulceration). Classic findings are microvascular intimal calcium deposition and fibrin thrombi, often accompanied by ischemic changes and/or necrosis of the fat as well as the overlying epidermis and dermis. A calcifying lobular panniculitis is also a common finding (Fig. 50.6A). Because calcium

Downloaded for Anonymous User (n/a) at Egyptian Knowledge Bank from ClinicalKey.com by Elsevier on March 10, 2024. For personal use only. No other uses without permission. Copyright ©2024. Elsevier Inc. All rights reserved.

deposits may be subtle in H&E-stained sections, von Kossa and Alizarin red stains are used to increase detection (Fig. 50.6B)[44]. The presence of both media calcification and thrombosis increases the specificity of skin biopsies[45].

Clinicopathologic correlation is required as vascular calcium deposits +/− thrombosis can be seen in patients with and without CKD in the absence of calciphylaxis[45,46]. Some clinicians have therefore proposed that just clinical features, alone or aided by radiographic findings, be utilized to establish the diagnosis due to the potential shortcomings of histopathology[47,48]. That said, to increase sensitivity, biopsy specimens should be obtained from the most active margin rather than ulcerated or necrotic areas. In the authors' opinion, when biopsies are performed, "double-punch" or telescoping techniques with adequate fat sampling are preferred over thin wedge biopsies[45], but this is still debated. The key is obtaining an adequate depth. Image-guided biopsy (e.g. by xeroradiography or ultrasound) may increase diagnostic yield. When penile calciphylaxis is suspected, diagnostic imaging with Doppler ultrasonography and a CT scan is recommended rather than performing a biopsy[49,50].

The differential diagnosis of calciphylaxis is outlined in Table 50.3.

Treatment of calciphylaxis including wound care

A multimodal approach is essential for the management of calciphylaxis. Contributing factors (e.g. calcium and iron supplementation, vitamin D intake) should be identified and addressed. For patients with end-stage CKD, potential interventions include increased frequency or duration of dialysis, low calcium dialysate, low phosphate diet, and phosphate binders[33]. While the value of altering dialysis parameters or types requires additional investigation, at least temporary conversion from peritoneal dialysis to hemodialysis may allow for treatment optimization[47,51,52].

When possible, warfarin should be discontinued and can be replaced by direct factor Xa inhibitors as this has been associated with improved survival[32]. Given the thrombotic component of calciphylaxis, institution of direct-acting oral anticoagulants (DOACs) or low-molecular-weight heparin should be considered in general, especially in those with thrombophilic conditions[53,54]. Calcimimetics (e.g. cinacalcet, etelcalcetide) that reduce PTH secretion via activation of calcium-sensing receptors can be administered for hyperparathyroidism, with parathyroidectomy reserved for those who fail to respond to medical management[47,55,56].

There are multiple reports of the successful use of sodium thiosulfate, but larger controlled studies are needed[37,57–61]. The proposed mechanisms of action include reduction of reactive oxygen species, vasodilation via hydrogen sulfide and nitric oxide production, solubilization of calcium, inhibition of calcium deposition[37], and improvement in vascular endothelial function[37,55]. Table 50.2 outlines the dosing regimens and side effects for both intralesional and intravenous sodium thiosulfate. In some patients, there may be a role for topical sodium thiosulfate.

There are additional therapies that may be considered. Bisphosphonates such as pamidronate and etidronate may be helpful in patients who fail to improve with sodium thiosulfate[66–69]. Vitamin K supplementation may help restore the functionality of vitamin K-dependent anti-calcification proteins (see above)[70–72]. Renal transplantation may be curative but calciphylaxis has also been reported following transplantation and transplantation carries additional risks in patients with large, open wounds[73,74].

In patients with ulcerations, intensive wound care, including autolytic or chemical debridement (see Ch. 105) and appropriate dressings (see Ch. 145), is required to maximize healing and minimize infection and pain. While some analyses have shown that overall survival is improved by surgical debridement, patients were not controlled for extent of disease[75,76]. Given the concern for Koebner phenomena in patients with active calciphylaxis, i.e. trauma leading to new lesions or worsening of disease, it has been suggested that wounds with clean bases or non-infected dry eschars not undergo surgical debridement[59,77–80]. When debridement is indicated to remove deeply necrotic or infected tissue, conservative removal of devitalized tissue, often feasible at the bedside, is preferred over larger excisional surgical procedures[32,47,76,79].

Hyperbaric oxygen therapy may promote more rapid wound healing and has a precedent in other ischemic diseases. Via delivery of highly concentrated pressurized oxygen, there is stimulation of fibroblast proliferation, collagen production, angiogenesis, and phagocytosis as well as reduction in anaerobic colonization[81–83]. A multidisciplinary team approach that includes the pain service, nutritionists, and physical therapists can optimize recovery.

CALCIPHYLAXIS AND ITS DIFFERENTIAL DIAGNOSIS

Disorder	Most common locations for purpuric lesions* +/or ulcerations	Risk factors
Calciphylaxis	• Sites of greater adipose tissue, e.g. breasts, thighs, abdomen, buttocks • Sites of trauma, including lower extremities	• End-stage chronic kidney disease, dialysis, obesity, diabetes mellitus, AI-CTDs, female sex, thrombophilia/hypercoagulability, use of warfarin or corticosteroids, liver disease, hyperparathyroidism, excess calcium/vitamin D ingestion, rapid weight loss
Warfarin (Coumadin®) necrosis	• Sites of greater adipose tissue, e.g. breasts, thighs, abdomen, buttocks	• Starting warfarin with a large loading dose or without concomitant heparin; appears 2–5 days after initiating treatment • Female sex, age >50 years
Cholesterol emboli	• Lower extremities, especially distally	• Recent catheterization, introduction of anticoagulants 1–2 months prior
Infectious emboli	• Distal extremities or more widespread	• Immunosuppression, endocarditis (including prosthetic heart valves), intravenous drug use, implanted intravascular devices
Vasculitis of medium-sized blood vessels	• Primarily lower extremities†	See Ch. 24
Diffuse dermal angiomatosis (DDA)	• Lower extremities, including thighs • Breasts • Abdomen	• Peripheral artery disease, usually severe • Macromastia • Obesity • Changes of DDA can overlie calciphylaxis
Vasculopathy/vasculitis due to levamisole-adulterated cocaine	• Lower extremities, ears • Can be widespread	• Use of cocaine via smoking, snorting, or injection (see Ch. 89)
Thrombophilia (hypercoagulability)	• Depends on underlying cause, e.g. more widespread in DIC versus more acral in type I cryoglobulinemia	See Tables 22.5 and 105.9
Oxalosis	• Acral	See Ch. 23

*Macular, plaques
†Also subcutaneous nodules.

Table 50.3 Calciphylaxis and its differential diagnosis. Especially when on the lower extremities, additional causes of ulceration (e.g. venous ulcer, hypertensive ulcer, pyoderma gangrenosum) need to be excluded before establishing a definitive diagnosis of calciphylaxis (see Ch. 105). AI-CTDs, autoimmune connective tissue diseases; DIC, disseminated intravascular coagulation.

Downloaded for Anonymous User (n/a) at Egyptian Knowledge Bank from ClinicalKey.com by Elsevier on March 10, 2024. For personal use only. No other uses without permission. Copyright ©2024. Elsevier Inc. All rights reserved.

Idiopathic Calcification

Idiopathic calcified nodules of the scrotum

The term "idiopathic calcified nodules of the scrotum" is used to describe firm, skin-colored to yellow–white nodules that develop on the scrotum, typically in men 20 to 40 years of age[84]. Scrotal calcinosis occurs more often in individuals with darker skin phototypes. There can be multiple lesions and they may be asymptomatic, pruritic, or ulcerated. Histologically, a calcified epidermoid cyst or eccrine duct cyst may be seen; however, often only dermal calcinosis, with or without a surrounding granulomatous foreign-body type reaction, is present. This has led to a debate as to whether these nodules represent idiopathic or dystrophic calcification[85–87]. A female equivalent, idiopathic calcinosis of the vulva, has also been described[84,88]. Surgical excision is performed for symptomatic lesions and for cosmetic concerns. CO_2 laser has emerged as an alternative therapeutic option[89].

Subepidermal calcified nodule

Subepidermal calcified nodules are smooth to verrucous, firm, yellow–white to erythematous papules or nodules that can be solitary or multiple. They favor the head and neck region, but also occur on the extremities[90]. Subepidermal calcified nodules usually develop in children but have been observed in all age groups. Trauma, perhaps *in utero*, or calcification of a pre-existing milium, eccrine duct hamartoma, or hair follicle nevus has been hypothesized as the cause. Histologically, focal amorphous masses of calcium with a surrounding inflammatory infiltrate are seen. Epidermal ulceration and transepidermal elimination of the calcium deposits occur frequently. Surgical removal is recommended for symptomatic lesions that do not self-resolve.

Tumoral calcinosis

Tumoral calcinosis may be either sporadic or familial. In both forms, patients develop large, often painful, deposits of calcium phosphate in the dermis and subcutaneous tissues around large joints (Fig. 50.7). Ulceration of the overlying skin may occur in larger lesions. The *sporadic* form is most often associated with secondary hyperparathyroidism due to advanced CKD[91].

Familial tumoral calcinosis is inherited in an autosomal recessive pattern and has both hyperphosphatemic and normophosphatemic forms[92]. The hyperphosphatemic form is most commonly due to mutations in *GALNT3*, which encodes N-acetylgalactosaminyltransferase 3 (ppGalNAc-T3), an enzyme that initiates mucin-type O-glycosylation[93]. It is hypothesized that this glycosylation regulates "phosphatonins" that in turn modulate circulating phosphate levels. Hyperphosphatemic familial tumoral calcinosis can also be caused by loss-of-function mutations in either *FGF23* or *KL*; the former encodes fibroblastic growth factor 23, a phosphaturic protein that is glycosylated by ppGalNAc-T3, while the latter encodes Klotho, a co-receptor for FGF23. Homozygous mutations in *SAMD9* (*s*terile *a*lpha *m*otif *d*omain containing 9), which encodes a protein involved in the regulation of extraosseous calcification, has been found to underlie normophosphatemic familial tumoral calcinosis in families of Jewish Yemenite origin[94].

Dietary phosphate restriction and antacids that inhibit phosphate absorption may be of some benefit, but surgical excision of symptomatic lesions remains the treatment of choice.

Milia-like calcinosis

Idiopathic calcinosis may sometimes take the form of small, milia-like lesions that develop on the dorsal surface of the hands and the face. Most commonly, these lesions appear in the setting of Down syndrome, although rarely they have been reported in patients without other medical issues[95,96]. In some patients, the calcinosis appears to result from calcification of pre-existing syringomas, but usually no precursor lesions can be found.

Iatrogenic Calcification

Iatrogenic calcification is due to the rapid precipitation of calcium salts within the skin. When the tissue concentration of calcium rises and exceeds the solubility product, calcium precipitates within the tissue, resulting in firm nodules within the dermis and/or subcutaneous tissue. A secondary inflammatory response is elicited and, over a period of weeks to months, the calcium is either absorbed or is transepidermally eliminated, depending on the depth of the deposit.

Iatrogenic calcification most commonly occurs with extravasation of calcium gluconate, calcium chloride, or calcium phosphate-containing intravenous solutions[97]. In a rabbit model of iatrogenic calcification, intralesional injections of triamcinolone into sites of extravasation decreased inflammation and ulceration. This treatment appeared to be most helpful when given immediately after the initial extravasation. Iatrogenic calcification has also been reported following prolonged electroencephalograms, electromyography, and brainstem auditory evoked potential testing when a high-calcium electrode paste is employed[98]. Several patients were noted to develop calcification in split-thickness skin graft donor sites following the use of calcium alginate dressings[99].

Transient cutaneous calcifications have been observed in patients following liver or lung transplantation[100]. They are generally small deposits in the skin that appear shortly after the transplant. They are hypothesized to arise as a consequence of the large amounts of calcium and blood products containing citrate required during surgery, combined with metabolic abnormalities during the perioperative period[101].

CUTANEOUS OSSIFICATION (OSTEOMA CUTIS)

There are four genetic disorders that often have cutaneous or subcutaneous ossification: fibrodysplasia ossificans progressiva, progressive osseous heteroplasia, plate-like osteoma cutis, and Albright hereditary osteodystrophy (Fig. 50.8). Of these disorders, *fibrodysplasia ossificans progressiva* differs from the others in that the bone formation is endochondral and involvement of the skin and subcutaneous tissue

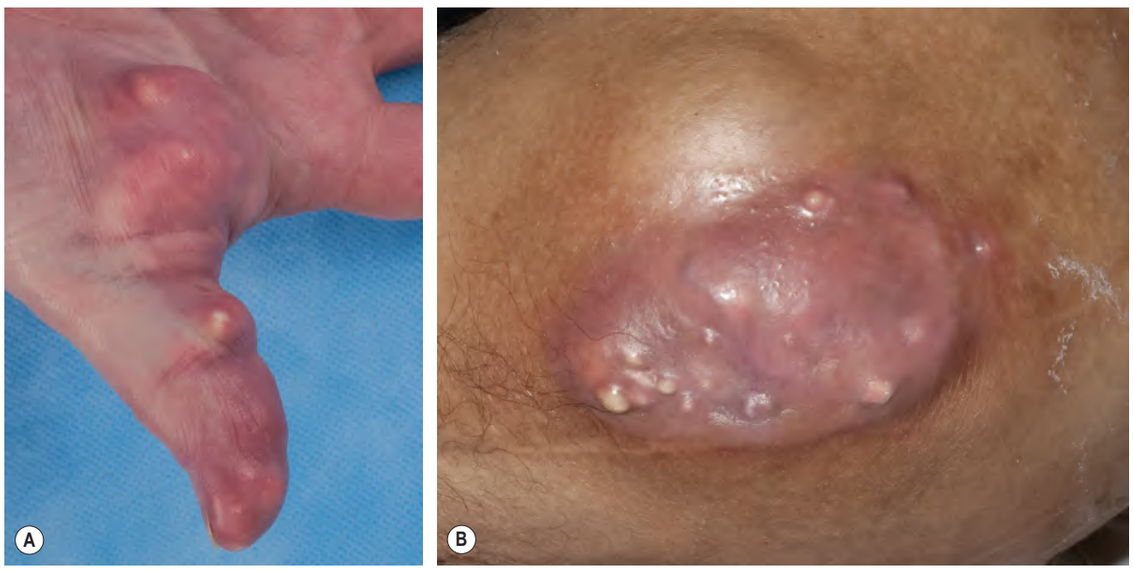

Fig. 50.7 Familial tumoral calcinosis. A, B There are large, frequently painful, deposits of calcium phosphate within the dermis and subcutaneous tissues, often around large joints. *Courtesy Edward Cowen, MD.*

Downloaded for Anonymous User (n/a) at Egyptian Knowledge Bank from ClinicalKey.com by Elsevier on March 10, 2024. For personal use only. No other uses without permission. Copyright ©2024. Elsevier Inc. All rights reserved.

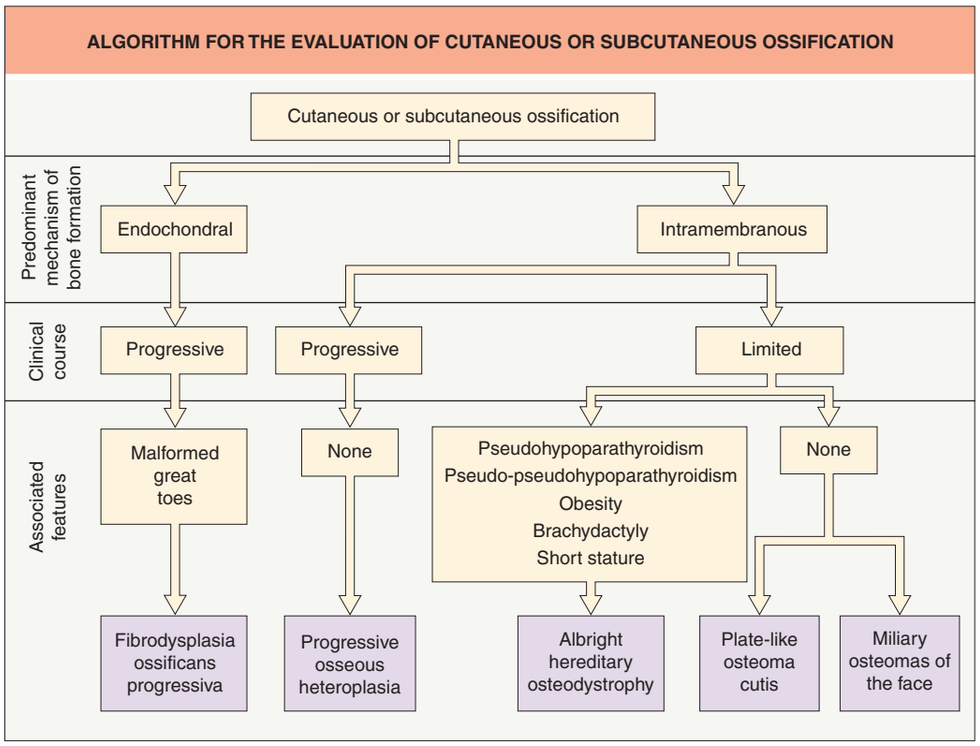

Fig. 50.8 Algorithm for the evaluation of cutaneous or subcutaneous ossification.

occurs only via extension from deeper tissues. These patients have extreme morbidity and often die at an early age due to restriction in movement of the chest. Fibrodysplasia ossificans progressiva is an autosomal dominant disorder with dysregulation of the bone morphogenic protein (BMP) signaling pathway. Heterozygosity for mutations in *ACVR1*, which encodes the activin A receptor (a BMP type I receptor), has been identified in both the inherited and sporadic forms of the disease. Of note, an arginine (R) to histidine (H) substitution at position 206 (R206H) was found not only in affected family members (i.e. the inherited form of the disease), but also in 30 of 32 *de novo* cases of fibrodysplasia ossificans progressiva, leading the authors to suggest that the R206H-associated mutation may represent one of the most specific codons in the human genome to be associated with a disease phenotype[102,103]. These patients are unlikely to present to a dermatologist due to their limited and late skin involvement.

Progressive osseous heteroplasia, plate-like osteoma cutis, and Albright hereditary osteodystrophy are all characterized by intramembranous ossification that begins in the dermis (Fig. 50.9). While distinctive features are seen in each of these entities, there is also considerable clinical overlap. The cutaneous lesions in *progressive osseous heteroplasia* are asymptomatic papules and nodules. Some are more plaque-like and studded with papules that give rise to a "rice-grain" texture. The lesions generally appear shortly after birth and may be rapidly progressive[104,105]. The location and extent of the ossification determines the associated morbidity; in general, there are no associated developmental or endocrine abnormalities. Unilateral involvement has also been described.

Plate-like osteoma cutis is considered to be a localized, non-progressive form of progressive osseous heteroplasia, with a single or limited number of sites of involvement[106]. *Albright hereditary osteodystrophy* is distinguished from these two entities by the presence of associated findings, including pseudohypoparathyroidism or pseudo-pseudohypoparathyroidism plus brachydactyly, obesity, short stature, and round facies. Fig. 50.8 demonstrates how clinical features may be used to classify these genetic disorders of cutaneous ossification.

Patients with progressive osseous heteroplasia, plate-like osteoma cutis, and Albright hereditary osteodystrophy all have mutations in the gene (*GNAS1*) that encodes the α-subunit of the stimulatory G protein which regulates adenyl cyclase activity[107,108]. The latter is believed to be a negative regulator of bone formation. Patients with progressive osseous heteroplasia have loss-of-function of the Gs-alpha isoform encoded by the **paternal** allele of *GNAS*, while those with Albright hereditary osteodystrophy have loss-of-function of the isoform encoded

Fig. 50.9 Osteoma cutis in Albright hereditary osteodystrophy. Hard pink–violet plaque studded with yellowish-white papules on the arm of an infant.
Courtesy Julie V. Schaffer, MD.

by the **maternal** allele of *GNAS*[109]. In other words, this locus is subject to imprinting (see Ch. 54), and different splice variants are expressed solely by maternal or paternal alleles[110].

Therapy for cutaneous ossification is difficult. Underlying abnormalities in calcium and/or phosphorus should be addressed; however, when complete ossification develops, the only therapeutic intervention is excision of neoformed bone. Even with surgical removal, recurrence of the bony deposits is common in this group of genetic disorders.

Miliary osteomas of the face is a fairly common entity characterized by multiple, scattered foci of cutaneous ossification. Small, firm papules appear on the face of adults and they can be skin-colored, white, or bluish (Fig. 50.10)[111]. Although these osteomas are often observed in the setting of chronic acne vulgaris, patients without a history of acne have also been reported. The unusual appearance of these osteomas on CT scan is shown in Fig. 50.10B. Histologically, islands of bone formation are seen in the dermis (Fig. 50.11).

Treatment of miliary osteoma cutis is primarily surgical. An incision over each lesion followed by gentle curettage of the bony

Downloaded for Anonymous User (n/a) at Egyptian Knowledge Bank from ClinicalKey.com by Elsevier on March 10, 2024. For personal use only. No other uses without permission. Copyright ©2024. Elsevier Inc. All rights reserved.

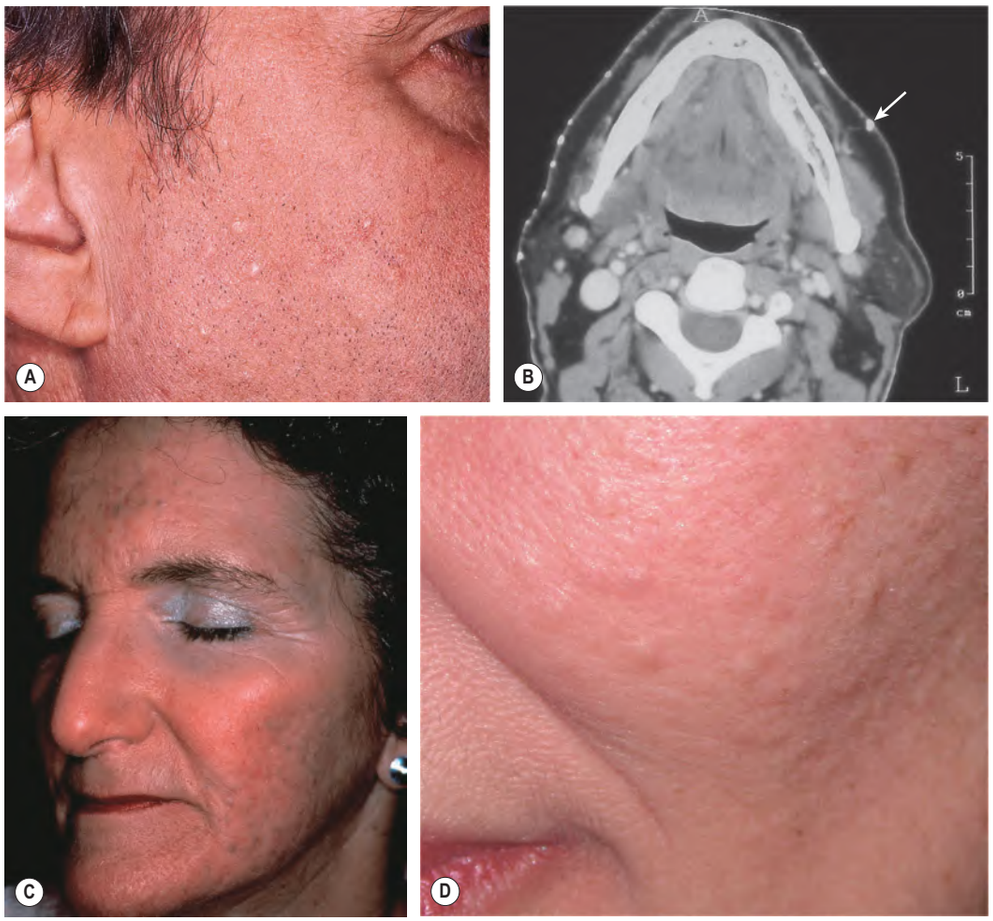

Fig. 50.10 Miliary osteoma cutis. A Multiple discrete white papules on the face of a patient with no previous history of acne. **B** The foci of ossification are readily apparent on the CT scan (arrow). **C, D** In contrast, many of the papules in these patients with a history of acne are skin-colored or blue.

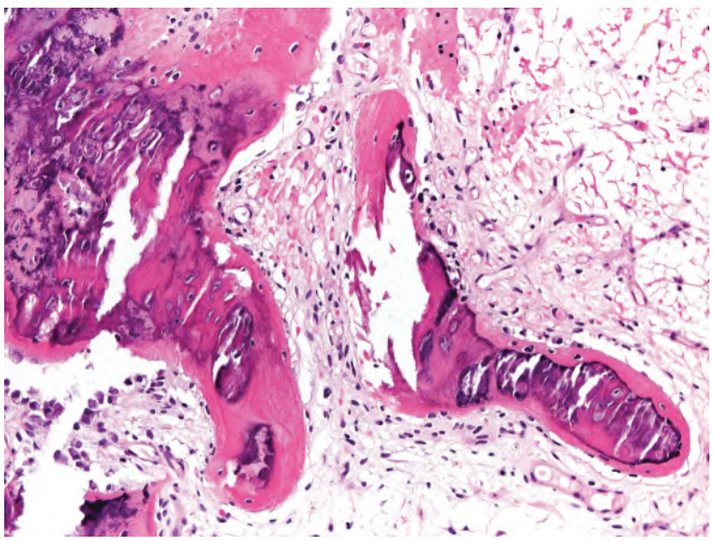

Fig. 50.11 Osteoma cutis – histologic features. Islands of bone formation are present within the dermis. Occasionally, osteoblasts and bone marrow elements can also be seen. *Courtesy Lorenzo Cerroni, MD.*

material with the edge of a surgical blade and then suture closure has been recommended. When lesions are numerous, however, this may not be practical. The use of lasers to expose osseous fragments has been reported[112,113]. Topical tretinoin gel may also be of some benefit[114].

"Secondary" Cutaneous Ossification

Ossification may develop as a secondary event. Most disorders in which calcification can be seen have also been reported to ossify. Ossification occurs as a result of inflammatory or neoplastic processes and is often preceded by calcification. Secondary ossification has been described in melanocytic nevi, pilomatricomas, pilar and epidermoid cysts, basal cell carcinomas, nephrogenic systemic fibrosis, and chronic calciphylaxis.

LABORATORY EVALUATION OF PATIENTS WITH CUTANEOUS CALCIFICATION/OSSIFICATION
Serum levels of: • Calcium • Phosphate • Parathyroid hormone (PTH) • Vitamin D_3 24-hour urinary calcium excretion Protein C activity and function (if calciphylaxis suspected) Genetic analysis (if hereditary disorder suspected)

Table 50.4 Laboratory evaluation of patients with cutaneous calcification/ossification.

LABORATORY EVALUATION OF PATIENTS WITH CUTANEOUS CALCIFICATION AND OSSIFICATION

In addition to a thorough history and physical examination focusing on the associated features that have been described, selected laboratory investigations may be helpful in the evaluation of calcifying and ossifying disorders. A summary of this evaluation is outlined in Table 50.4. Abnormalities are expected most often in association with metastatic causes of calcification (see Table 50.1). Serum calcium and phosphate levels should be obtained in order to calculate the calcium × phosphate product. While this may give a general clue regarding the patient's metabolic status with regard to calcium and phosphate, a normal value does not necessarily exclude these disorders. There are rare reports of patients with calcinosis cutis and a normal serum calcium level, but abnormally low urinary excretion of calcium; thus, an assessment of the 24-hour urinary calcium excretion may be warranted in some patients.

Additional figures available in our eBook (see inside front cover for access code).

Downloaded for Anonymous User (n/a) at Egyptian Knowledge Bank from ClinicalKey.com by Elsevier on March 10, 2024. For personal use only. No other uses without permission. Copyright ©2024. Elsevier Inc. All rights reserved.

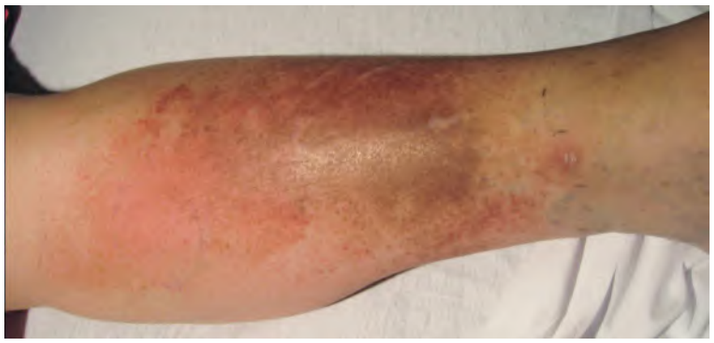

eFig. 50.1 Early in the course of calciphylaxis, there is painful erythema that can mimic cellulitis. *Courtesy Anthony Cukras, MD, PhD*.

eFig. 50.2 Calciphylaxis in a patient with end-stage chronic kidney disease. Typical reticulated, violaceous plaques that usually precede ulceration. *Courtesy Kalman Watsky, MD*.

eFig. 50.3 Calciphylaxis in a patient with end-stage chronic kidney disease. Early lesion on the leg with retiform purpura but no ulceration.

eFig. 50.4 Calciphylaxis in a patient with end-stage chronic kidney disease. Lower extremity ulceration accompanied by retiform purpura.

Downloaded for Anonymous User (n/a) at Egyptian Knowledge Bank from ClinicalKey.com by Elsevier on March 10, 2024. For personal use only. No other uses without permission. Copyright ©2024. Elsevier Inc. All rights reserved.

eFig. 50.5 Calciphylaxis characterized by irregular purpuric plaques in the girdle area with an ulceration covered by a black eschar.

eFig. 50.6 Calciphylaxis. A thick black eschar overlies an ulceration.

eFig. 50.7 Calciphylaxis in a patient with end-stage chronic kidney disease. Large ulceration on the leg with a black eschar and retiform purpura in surrounding skin.

eFig. 50.8 Calciphylaxis in a patient with end-stage chronic kidney disease. Large ulceration on the leg with a fibrinous base and a black eschar superiorly.

Downloaded for Anonymous User (n/a) at Egyptian Knowledge Bank from ClinicalKey.com by Elsevier on March 10, 2024. For personal use only. No other uses without permission. Copyright ©2024. Elsevier Inc. All rights reserved.

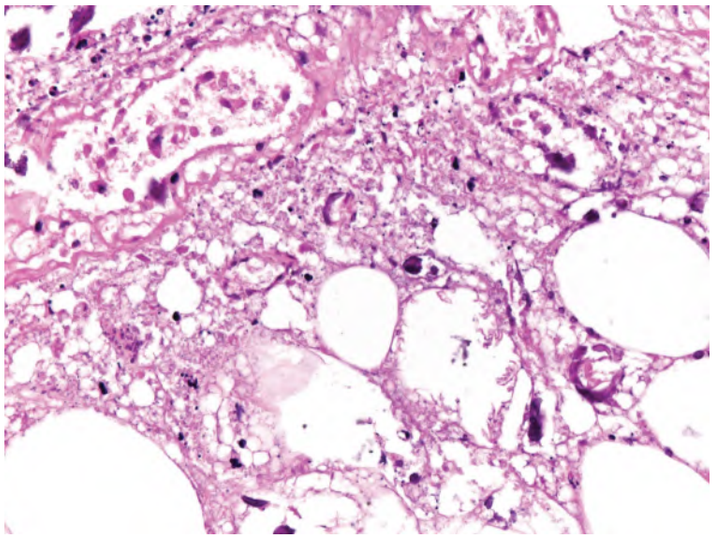

eFig. 50.9 Calciphylaxis – histopathologic features. Deposition of calcium is seen within the walls of blood vessels in the subcutaneous fat, in addition to diffuse calcification within the connective tissue. *Courtesy Lorenzo Cerroni, MD*.

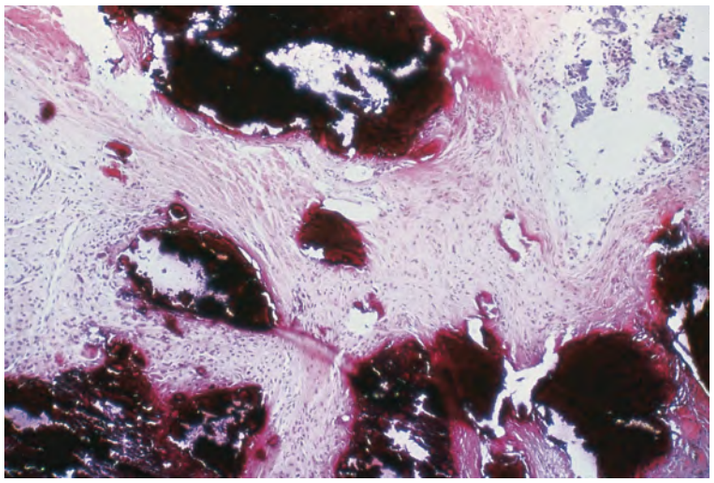

eFig. 50.10 Progressive osseous heteroplasia – histologic features. Deposits of calcium are seen more superficially, often with foci of cartilage and bone formation in the subcutaneous tissue.

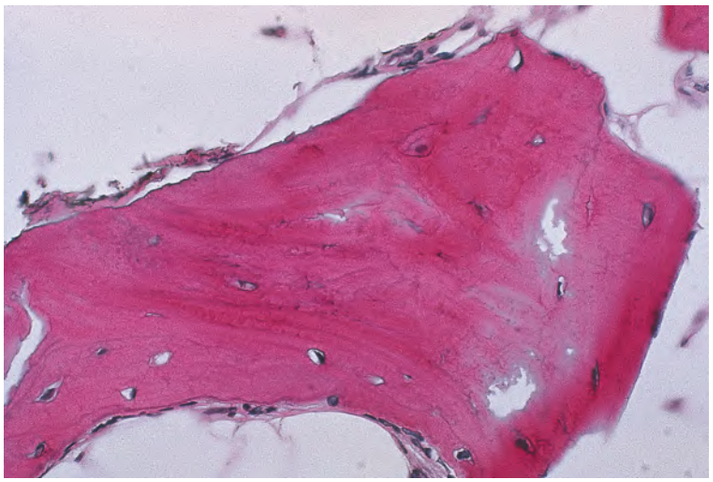

eFig. 50.11 Osteoma cutis – histologic features. Islands of bone formation are present within the dermis. Occasionally, osteoblasts and bone marrow elements can also be seen.

Downloaded for Anonymous User (n/a) at Egyptian Knowledge Bank from ClinicalKey.com by Elsevier on March 10, 2024. For personal use only. No other uses without permission. Copyright ©2024. Elsevier Inc. All rights reserved.